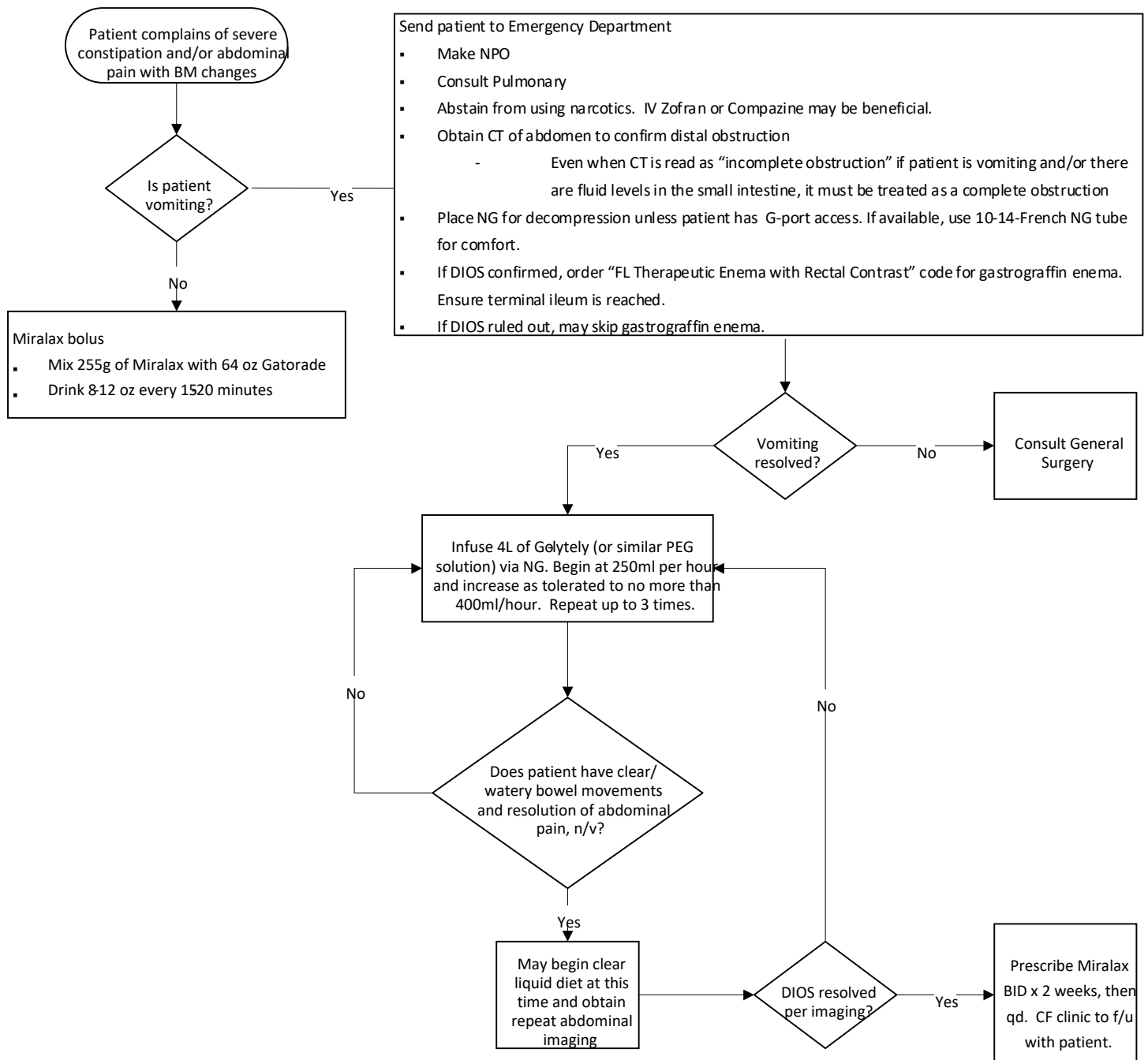


# Management of Constipation and DIOS in Cystic Fibrosis, Inpatient and Outpatient

Updated: October 3, 2023

## Clinical Algorithm:



# Clinical Pathway Summary

**CLINICAL PATHWAY NAME:** Management of constipation and distal intestinal obstructive syndrome (DIOS) in Cystic Fibrosis (CF)

**PATIENT POPULATION AND DIAGNOSIS:** Adult cystic fibrosis patients

**APPLICABLE TO:** Corewell Health Adult Cystic Fibrosis Care Team, Corewell Health Lung Transplant Team, Corewell Health Inpatient (all facilities)

**BRIEF DESCRIPTION:** People with cystic fibrosis are at high risk for distal intestinal obstructive syndrome due to large amounts of mucus and sticky stool in their intestines, intestinal dysmotility and dehydration. A person with CF may be at even higher risk if they have had an episode of DIOS in the past or have had one or more bowel resections.<sup>1</sup> Distinguishing between constipation and DIOS is crucial to prevent bowel perforation or unnecessary surgery. Constipation in CF is characterized by abdominal pain, distention, gradual decrease in bowel movements over several days to weeks and can typically be treated with laxatives.<sup>2</sup> DIOS is characterized by vomiting of bile and/or fluid in the small intestine as visualized by an abdominal film, a large amount of stool in the ileocecum, and abdominal pain or distention.<sup>2</sup> Treating DIOS with a gastrograffin enema allows stool to be broken up and pass through the bowel. Treating a patient with a complete obstruction with laxatives before the stool mass is removed may increase the risk of perforation.

**OPTIMIZED EPIC ELEMENTS (if applicable):** CF order set TBD

**IMPLEMENTATION DATE:** July 17, 2023

**LAST REVISED:** October 3, 2023

## Clinical Pathways Clinical Approach

### TREATMENT AND MANAGEMENT<sup>3</sup>:

- A. The first step in treatment is determining if the patient has constipation or DIOS. If a patient calls the outpatient clinic or presents to the ED with severe constipation and/or abdominal pain with bowel changes (can also present as diarrhea from overflow of stool), the first symptom to rule out is vomiting.
  - I. If the patient is not vomiting, the patient may be treated with a large bolus of 64 ounces of Gatorade mixed with 255 grams of Miralax. This should be consumed at a rate of about 8-12 ounces every 15-20 minutes.
    - a. If the patient cannot tolerate oral administration, an NG tube may be placed for delivery.
  - II. If the patient has symptoms of DIOS (vomiting, especially of bile, and abdominal pain) the patient should be sent to the emergency department and be made NPO until DIOS can be ruled out. The patient may be given IV Zofran or Compazine, but use of narcotics should be avoided which may worsen the obstruction. A CT of the abdomen should be obtained to confirm a distal obstruction. Even if the CT is read as “incomplete obstruction” if the patient is vomiting and/or there is fluid in the small intestine, the patient should be treated as though they have a complete obstruction.
    - a. Unless the patient already has G-port access, an NG must be placed for decompression. This should ideally be performed by a skilled clinician to avoid multiple attempts. A 10-14-French NG provides less irritation than a 16-French NG but is also able to suction contents of the stomach.
    - b. If DIOS is confirmed, an order for a “fluoroscopic therapeutic enema with rectal contrast” should be placed for a gastrograffin enema. A gastrograffin enema is a rectal lavage with hydrostatic pressure under direct vision by an experienced radiologist until terminal ileum is reached.

- i. If the gastrograffin enema was unsuccessful or if vomiting persists, consult general surgery
  - c. If the gastrograffin enema was successful and the patient has stopped vomiting, begin infusion of 4L of Go-lytely (or similar poly-ethylene glycol solution) via the NG. Initiate a rate of 250ml per hour and increase as tolerated to no more than 400ml per hour.
    - i. This step can be repeated up to 3 times if needed.
  - d. If the patient has clear, watery bowel movements and resolution of abdominal pain and nausea, then the patient may be advanced to a clear liquid diet and a repeat CT of the abdomen should be obtained.
    - i. If the scan continues to reveal a stool burden, repeat the infusion of Go-lytely.
    - ii. If the scan shows resolution of DIOS, the NG may be removed.
  - e. Order Miralax to be taken twice daily for two weeks, then patient to remain on one dose daily until told otherwise.
- III. If the CT scan of the abdomen does not show fluid levels in the small intestine and vomiting is not bilious, the provider may try skipping the gastrograffin enema and only order the Go-lytely infusion (via NG or po as tolerated). Repeat steps II d and II e.

## Pathway Information

**OWNER(S):** Molly Bigford, MS, RD, CACFD

**CONTRIBUTOR(S):** Shannon Jansma, PA-C

**EXPERT IMPROVEMENT TEAM (EIT):** N/A

**CLINICAL PRACTICE COUNCIL (CPC):** Specialty/Digestive

**CPC APPROVAL DATE:** July 17, 2023

**OTHER TEAM(S) IMPACTED:** Pulmonary, Interventional Radiology, Lung Transplant Team, Gastrointestinal/Digestive, General Surgery, Emergency Department

## References

1. Abraham JM, Taylor CJ. Cystic Fibrosis & disorders of the large intestine: DIOS, constipation, and colorectal cancer. *J Cyst Fibros.* 2017;16 Suppl 2:S40-S49.
2. Houwen RH, van der Doef HP, Sermet I, et al. Defining DIOS and constipation in cystic fibrosis with a multicentre study on the incidence, characteristics, and treatment of DIOS. *J Pediatr Gastroenterol Nutr.* 2010;50:38-42.
3. Abraham, JM, Sabharwal, S, Grand, R, Mascarenhas, M. Recommendations of the task force on distal intestinal obstruction syndrome. *Cystic Fibrosis Foundation, Bethesda, MD, USA; 2016.*