

Case Report

Prepatellar bursitis due to *Brucella abortus*: case report and analysis of the local immune response

Jorge C. Wallach,¹ M. Victoria Delpino,² Romina Scian,² Bettina Deodato,³ Carlos A. Fossati² and Pablo C. Baldi²

Correspondence

Pablo C. Baldi
pablobal@ffybu.uba.ar

¹Servicio de Brucelosis, Hospital F. J. Muñiz, Buenos Aires, Argentina

²Instituto de Estudios de la Inmunidad Humoral (IDEHU), Facultad de Farmacia y Bioquímica, Universidad de Buenos Aires, Buenos Aires, Argentina

³Laboratorio de Bacteriología, Hospital F. J. Muñiz, Buenos Aires, Argentina

A case of prepatellar bursitis in a man with chronic brucellosis is presented. *Brucella abortus* biotype 1 was isolated from the abundant yellowish fluid obtained from the bursa. Clinical and epidemiological data did not suggest a direct inoculation of the agent in the bursa. However, the patient mentioned occasional local trauma due to recreational sports, which may have constituted a predisposing factor. As determined by ELISA, there were higher levels of IgG against *Brucella* LPS and cytosolic proteins detected in the patient's bursal synovial fluid when compared with serum. Levels of proinflammatory cytokines (tumour necrosis factor alpha, interleukin 1 beta, gamma interferon, interleukin 8 and MCP-1) were higher than in synovial fluids obtained from patients with rheumatoid arthritis and a patient with septic arthritis, and a zymographic analysis revealed a gelatinase of about 92 kDa. These findings indicate that it may be possible to diagnose brucellar bursitis by measuring specific antibodies in the bursal synovial fluid. In addition, our findings suggest a role of increased local levels of proinflammatory cytokines and gelatinases in the inflammatory manifestations of brucellar bursitis.

Received 30 September 2009
Accepted 16 August 2010

Introduction

Bursae are closed sacs located around joints and tendon insertions, which facilitate the gliding of connective tissue structures against one another during movement. These sacs have a synovial lining similar to that of diarthrodial joints. The prepatellar bursa overlies the patella, and is distinct and separate from the knee joint. Bursal inflammation (bursitis) may occur from many causes, including acute trauma, chronic friction, crystal deposition (e.g. gout and pseudogout), infection and systemic diseases [e.g. rheumatoid arthritis (RA)]. Bursitis may involve either superficial or deep bursae. Most cases of septic bursitis (50–70%), mainly those affecting superficial bursae, occur from direct penetration of micro-organisms through traumatic injury or through contiguous spread from cellulitis. Less commonly, infection of deep or superficial bursae is due to contiguous septic arthritis or results from haematogenous spread (10% of cases). The most common causative organism is *Staphylococcus aureus* (80% of cases), followed by streptococci. Other less frequent organisms include enterococci and occasionally Gram-negative bacteria. There have been also reports of cases due to

mycobacteria (both tuberculous and nontuberculous strains), anaerobes, fungi (*Candida*) and algae (*Prototheca wickerhamii*) (Zimmermann *et al.*, 1995; Small & Ross, 2005).

Osteoarticular involvement is frequent in brucellosis and usually manifests as sacroiliitis, arthritis and spondylitis, while bursitis is a rare event (Mousa *et al.*, 1987; Taşova *et al.*, 1999; Pourbagher *et al.*, 2006). *Brucella* is also a rare cause of bursitis as compared to other micro-organisms (Small & Ross, 2005). Although human brucellosis is endemic in Argentina, we are not aware of any previous report of brucellar bursitis in our country. Here we report a case of prepatellar bursitis due to *Brucella abortus*, and describe our findings regarding the presence of inflammatory markers and locally produced antibodies in the bursal fluid.

Case report

A 48-year-old man sought medical care in March 2007 because of recurrent asthenia, myalgia, arthralgia and rachi-
algia during the previous 4 years. At the time of examination the patient was afebrile, and no sign of pathology was detected. However, abdominal ultrasonography revealed slight homogeneous splenomegaly, a cyst-like lesion of 13 mm in the right hepatic lobe, perihepatic adenopathy

Abbreviations: IFN- γ , gamma interferon; IL, interleukin; MMP, metalloproteinase; RA, rheumatoid arthritis; STA, standard tube agglutination; TNF- α , tumour necrosis factor alpha.

and lithiasis in the right kidney. Haematological and clinical chemistry parameters were within normal values.

In an interview the patient indicated that he had worked in a bovine slaughterhouse during the last 5 years, and that he had made sporadic visits to a rural area where he had contact with pigs and occasionally consumed raw dairy products. He had also had pneumonitis in 2004 and frequent knee trauma related to recreational sports. In view of the clinical findings, and the history of contact with animals and animal tissues, brucellosis was suspected. Blood cultures were negative, but specific serological tests yielded results compatible with active brucellosis. The Rose Bengal, standard tube agglutination (STA) and complement fixation tests were performed according to standard procedures (Alton *et al.*, 1988). The United States Department of Agriculture technique was used for STA (doubling serum dilutions starting at 1/25), and doubling serum dilutions starting at 1/5 were used for complement fixation. The serum obtained from the patient yielded a positive result in the Rose Bengal test, a titre of 1/100 in the STA test and a titre of 1/10 in the complement fixation test. In the competitive ELISA (performed according to Lucero *et al.*, 1999) an inhibition of 91% was obtained (values higher than 28% are considered positive). Antimicrobial therapy was initiated with doxycycline, which was combined with co-trimoxazole because a pre-existing bilateral hearing loss precluded the use of aminoglycosides. The patient had a favourable clinical outcome and did not return for the scheduled follow-up examinations.

One year later the patient sought medical care because of low back pain and right knee inflammation. A thorough clinical examination disclosed signs compatible with prepatellar bursitis, including swelling and redness in the prepatellar region (Fig. 1a), and a puncture of the affected bursa yielded abundant yellowish fluid. Synovial fluid samples were inoculated onto blood agar, chocolate agar and into thioglycolate broth to investigate the presence of bacteria. In addition, samples were inoculated in liquid media for aerobic and anaerobic culture in the BacT/ALERT system and in *Brucella* broth (Difco) supplemented with 3% horse serum. BacT/ALERT cultures that yielded bacterial growth were subcultured on both blood agar and chocolate agar for 72 h at 37 °C in a 5% CO₂ atmosphere. Bacteria were isolated from synovial fluid in all the culture media (except in thioglycolate broth), and in every case were identified as *Brucella* spp. on the basis of the catalase, oxidase, urea and TSI (triple sugar iron) reactions. Cultures were sent to a reference laboratory, where they were typed as *B. abortus* biotype 1. Serological tests performed at the time of this relapse revealed a persistence of active brucellosis, as indicated by positive results in the Rose Bengal test and the competitive ELISA, and in indirect ELISA tests developed in our laboratory to measure antibodies to LPS and the LPS-free cytosolic fraction (cytosolic proteins) of *B. abortus* (Baldi *et al.*, 1996) (Table 1). Antibodies to LPS and cytosolic proteins were also measured by ELISA in samples of prepatellar synovial

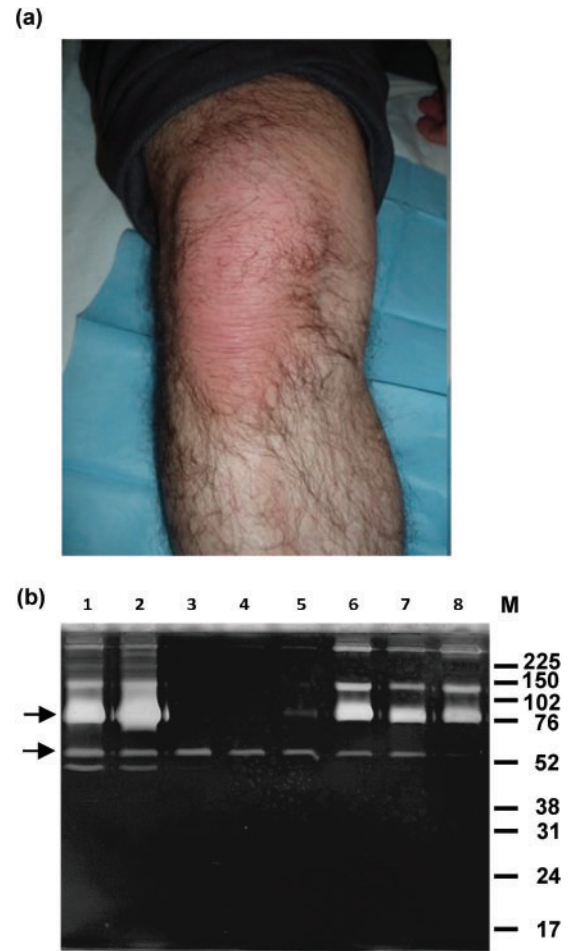


Fig. 1. (a) Prepatellar bursitis in the right leg of a patient with brucellosis. (b) Zymographic analysis of gelatinase activity in the bursal synovial fluid of the patient (lane 1, sample taken at presentation; lane 2, sample taken 3 weeks later), and in the articular synovial fluid of five patients with RA (RA 1 to RA 5, lanes 3 to 7) and one patient with septic arthritis (lane 8). Diluted synovial fluid samples were subjected to electrophoresis in polyacrylamide gels containing gelatin. After incubation with appropriate buffers to restore gelatinase activity, the gels were stained with Coomassie blue. Gelatinase activity in the regions of molecular mass around 90 and 60 kDa is indicated by the upper and lower arrows, respectively.

fluid obtained at presentation and 3 weeks later. For both serum and synovial fluid samples, ELISA titres were established by end-point titration of doubling dilutions starting at 1/100. Notably, ELISA titres in synovial fluid were higher than those detected using the same tests in serum samples obtained at the time of relapse (Table 1). No IgM against LPS or cytosolic proteins was detected in any synovial sample.

A second course of antimicrobial therapy with doxycycline (100 mg twice daily) and rifampicin (300 mg twice daily) for 6 weeks led to the resolution of bursitis. However,

Table 1. Detection of anti-*Brucella* antibodies by conventional serological tests and in-house ELISA tests in serum and bursal synovial fluid samples from the bursitis case

STA, CF and Rose Bengal tests were performed as described by Alton *et al.* (1988). IgG antibodies to LPS and CP were titrated by indirect ELISA (doubling dilutions starting at 1/100) as described by Baldi *et al.* (1996). The C-ELISA was performed according to Lucero *et al.* (1999).

	Result of serological test*	
	At presentation	3 weeks later
Rose Bengal	Positive	Positive
STA†	25	50
CF	5	5
C-ELISA	67	68
Serum anti-LPS IgG	12 800	12 800
Serum anti-CP IgG	Negative	Negative
Synovial anti-LPS IgG	5 1200	5 1200
Synovial anti-CP IgG	800	1600

C-ELISA, Competitive ELISA; CF, complement fixation; CP, cytosolic proteins.

*Results are expressed as titres except for the Rose Bengal test (positive/negative) and the C-ELISA (percentage of inhibition). Samples are sera unless otherwise indicated, and were obtained at presentation of bursitis and 3 weeks later.

simultaneously the patient presented with right hip arthralgia, and computed tomography images revealed signs of synovitis in that location. Unfortunately, the patient discontinued medical treatment and was lost to follow-up examination.

Inflammatory markers in the prepatellar synovial fluid

The levels of several inflammatory cytokines and chemokines in the two synovial fluid samples mentioned above (initial presentation of bursitis and 3 weeks later) were

measured by commercial ELISA kits (BD Pharmingen). For comparison, five samples of synovial fluid from patients with RA and one sample from one patient with septic arthritis of the knee due to *S. aureus* were also tested. As shown in Table 2, levels of tumour necrosis factor alpha (TNF- α), interleukin (IL-)8 and MCP-1 were markedly elevated in the two synovial fluid samples of the bursitis patient as compared to RA and septic arthritis samples. Regarding IL-1 β and gamma interferon (IFN- γ), levels in the bursitis sample from the initial presentation were similar to those detected in septic arthritis and some RA patients, but levels in the bursitis sample obtained 3 weeks later were notably higher. Interestingly, the levels of each cytokine increased between the sample obtained at bursitis presentation and that obtained 3 weeks later, suggesting an ongoing inflammatory process.

Other molecules upregulated in inflammatory reactions and usually involved in inflammatory tissue destruction are matrix metalloproteinases (MMPs), some of which have gelatinase activity. A zymographic method (Kleiner & Stetler-Stevenson, 1994) was used to measure gelatinase activity in the synovial fluid samples of the bursitis case, and in those obtained from RA and septic arthritis patients. Briefly, the acellular fraction of the synovial fluid was diluted 1/10 in PBS (0.15 M NaCl, 10 mM phosphate buffer, pH 7.2), and 4 μ l of this dilution were mixed with sample buffer and subjected to PAGE in 10% gels containing 0.1% (w/v) gelatin. After the electrophoresis run, the gel was subjected to two sequential incubations (45 min each) with 50 mM Tris/HCl pH 7.5 containing 2.5% Triton X-100 and the same buffer with added 5 mM CaCl₂ and 1 μ M ZnCl₂. Then, the gel was incubated for 24 h with 50 mM Tris/HCl pH 7.5 containing 10 mM CaCl₂ and 200 mM NaCl before staining with Coomassie blue. The presence of unstained bands indicates the presence of gelatinase activity. A gelatinase band at around 90 kDa is attributed to MMP-9, while gelatinase bands around 60 kDa are attributed to MMP-2 (Snoek-van Beurden & Von den Hoff, 2005). A protein with gelatinase activity was detected at about 90 kDa (suggesting the presence of MMP-9) in the two samples from the bursitis

Table 2. Comparison of inflammatory cytokine and chemokine levels in synovial fluid taken at presentation and 3 weeks later from a patient with brucellar bursitis with synovial fluid from RA cases and a case of septic arthritis

The results (expressed in ng ml⁻¹) are the means of duplicate measures, with the ranges of the values shown in parentheses.

Sample	TNF- α	IL-1 β	IFN- γ	IL-8	MCP-1
Bursitis (at presentation)	34.36 (32.24–36.47)	7.51 (7.12–7.90)	14.57 (10.13–19.00)	9.53 (9.30–9.75)	11.81 (0.72)
Bursitis (3 weeks later)	79.73 (76.34–83.12)	16.62 (15.08–18.16)	22.45 (20.04–24.87)	25.55 (25.23–25.89)	16.35 (1.23)
Septic arthritis	3.95 (3.90–4.00)	9.75 (9.50–10.01)	7.30 (7.00–7.60)	4.75 (4.50–5.00)	3.41 (3.40–3.42)
RA 1	4.68 (4.67–4.70)	3.32 (3.20–3.45)	10.50 (10.05–11.00)	3.62 (3.50–3.73)	2.10 (2.00–2.21)
RA 2	5.99 (5.98–6.00)	3.55 (3.50–3.60)	15.55 (15.10–16.00)	3.25 (3.20–3.30)	1.57 (1.53–1.60)
RA 3	3.37 (3.30–3.45)	2.77 (2.75–2.80)	8.05 (8.00–8.10)	4.05 (4.00–4.10)	1.15 (1.00–1.29)
RA 4	13.67 (13.60–13.74)	10.50 (10.00–11.00)	8.95 (8.90–9.00)	4.17 (4.14–4.20)	0.85 (0.84–0.85)
RA 5	8.11 (8.00–8.23)	9.73 (9.67–9.80)	12.15 (12.00–12.30)	4.14 (4.00–4.28)	2.27 (2.19–2.34)

case, two of the RA case samples and the septic arthritis case sample (Fig. 1b). A minor gelatinase activity between 52 and 76 kDa (which may correspond to MMP-2) was also detected in all the samples, except for that from the septic arthritis case.

The expression of surface markers by cells present in the sample of synovial fluid obtained three weeks after presentation was analysed by flow cytometry using previously described methods (Zwerdling *et al.*, 2008). The percentage of positive cells was 67.1 % for CD1a, 93.9 % for CD11b, 87.3 % for CD14, 92.8 % for CD35, 0.9 % for CD40, 85.8 % for CD64, 69.5 % for CD83, 47.3 % for CD86, 98.4 % for MHCI and 54.7 % for MHCII. These results suggested a preponderance of monocytic cells (monocytes, macrophages and dendritic cells) in the inflammatory synovial fluid.

Discussion

The percentage of brucellosis patients presenting with bursitis has been reported to range from 0.4 to 5.2 %, which represents 1.2 to 9.0 % of patients with osteoarticular brucellosis (Mousa *et al.*, 1987; Taşova *et al.*, 1999; Pourbagher *et al.*, 2006). It must be noted, however, that the highest percentages correspond to studies in which the condition was diagnosed by ultrasonography of the affected joint. In spite of the high prevalence of human brucellosis in Argentina, this is to the best of our knowledge the first case of brucellar bursitis reported in our country. This exceptional finding may be due in part to the fact that ultrasonographical screening is not routinely performed in Argentina on brucellosis patients with osteoarticular involvement.

The prepatellar bursa is the most common site of brucellar bursitis. In contrast with prepatellar bursitis due to staphylococci, in which infection is usually attributed to direct percutaneous penetration of bacteria at the site of kneeling (Zimmermann *et al.*, 1995), bursitis due to *Brucella* spp. probably results from haematogenous dissemination (Small & Ross, 2005). However, some authors have attributed the predominance in brucellosis of prepatellar bursitis, as compared to other locations, to local trauma resulting from frequent kneeling in people handling animals (Traboulsi *et al.*, 2007). Our patient, however, was not involved in an activity involving frequent kneeling. In addition, he did not exhibit skin lesions, one of the factors considered to support a direct transcutaneous route of infection (Zimmermann *et al.*, 1995). The fact that the contiguous knee joint was unaffected suggests that the infection was not secondary to a septic arthritis. Previous non-infectious inflammation of the bursa resulting from gout, RA or trauma is recognized as a predisposing factor for septic bursitis (Zimmermann *et al.*, 1995; Small & Ross, 2005). The patient's medical records were negative for gout or RA, but the patient recalled a probable bursitis as a result of trauma during recreational sports (soccer). This fact, combined with the chronic nature of his brucellosis,

may have produced a favourable condition for the development of brucellar bursitis. However, since bursitis also has been described in patients without a history of trauma, the apparent temporal relationship between bursitis and sport trauma in our patient may have been purely coincidental. Our patient did not exhibit other conditions recognized as predisposing factors for the development of septic bursitis, such as diabetes mellitus or chronic alcohol abuse (Small & Ross, 2005).

The intra-articular production of specific antibodies against pathogens has been shown in several types of infectious arthritis (Bas *et al.*, 2001; Cruz *et al.*, 1990), but to the best of our knowledge no studies have documented the local production of antibodies in septic bursitis. In the present case, the immunological tests performed on the bursal synovial fluid suggested the local production of anti-*Brucella* antibodies as indicated by higher titres of antibodies against both LPS and cytoplasmic proteins in the synovial fluid than in serum. Although this finding needs to be confirmed in additional brucellar bursitis cases, it suggests that serological tests on samples of bursal synovial fluid may help to establish a rapid diagnosis of brucellar bursitis while the results of bacteriological studies are awaited. The ELISA tests used in the present study to evaluate locally produced antibodies have been previously shown to be useful for diagnosing active brucellosis (Baldi *et al.*, 1996).

To the best of our knowledge, there are no published studies on the inflammatory pathophysiological mechanisms involved in septic bursitis. However, several studies have explored inflammation markers in septic arthritis. Since both the bursa and the joint cavity are delimited by a synovial lining, it is probable that the inflammatory reaction against pathogens is similar at both sites. Studies on septic arthritis in humans have revealed increased levels of proinflammatory cytokines and MMPs in the synovial fluid of patients (Hu *et al.*, 2001; Shin *et al.*, 2007). Despite the lack of information on inflammatory mediators in septic bursitis, some reports on subacromial bursitis in rotator cuff disease have documented an increased expression of proinflammatory cytokines, such as TNF- α , IL-1 β and IL-6, as well as MMPs in bursa biopsy specimens (Blaine *et al.*, 2005; Voloshin *et al.*, 2005). It is conceivable that such proteins are also produced during the inflammatory processes caused by septic bursitis, and are secreted to the synovial fluid. In line with this hypothesis, high levels of TNF- α and IL-1 β were detected in the synovial fluid of our patient, together with increased levels of proinflammatory chemokines (IL-8 and MCP-1), IFN- γ and MMP-9. Levels of TNF- α , IL-8 and MCP-1 measured in both samples of bursitis synovial fluid were higher than those detected in septic arthritis and RA samples, and the same was true for IL-1 β and IFN- γ in the synovial fluid sample taken at 3 weeks after presentation. Levels of all the inflammatory markers assessed were increased in the later sample as compared to the initial sample. These mediators probably interact locally to mount and sustain the

inflammatory process. It is well established that proinflammatory cytokines can stimulate the secretion of MMPs by several cell types, including monocytes, chondrocytes and synoviocytes (Murphy & Nagase, 2008). Notably, gelatinase activity as detected by zymography was more evident in the bursitis case and the synovial fluids of the septic arthritis and RA cases that exhibited the highest TNF- α and/or IL-1 β levels (Fig. 1b).

In summary, we have presented a case of prepatellar brucellar bursitis, which is a rare finding not only among brucellosis patients but also among bursitis patients. The investigations performed on this patient have revealed a local production of anti-*Brucella* antibodies in the bursa, which suggests the possibility of diagnosing brucellar bursitis by measuring such antibodies in the bursal synovial fluid. Our studies have also shown increased levels of proinflammatory cytokines and gelatinases in the bursal fluid, which may mediate the inflammatory manifestations of brucellar bursitis.

Acknowledgements

We are grateful to Miriam Mortarini for bacteriological studies, to Nidia Lucero for *Brucella* typing and C-ELISA tests, and to Astrid Zwerdling for flow cytometry studies. This work was supported by a grant from Agencia Nacional de Promoción Científica y Tecnológica (ANPCYT) (PICT 00517), and by a grant from Fundación Roemmers.

References

- Alton, G. G., Jones, L. M., Angus, R. D. & Verger, J. M. (1988). *Techniques for the Brucellosis Laboratory*, 2nd edn. Paris: Institut National de la Recherche Agronomique (INRA).
- Baldi, P. C., Miguel, S. E., Fossati, C. A. & Wallach, J. C. (1996). Serological follow-up of human brucellosis by measuring IgG antibodies directed to LPS and cytoplasmic proteins of *Brucella*. *Clin Infect Dis* **22**, 446–455.
- Bas, S., Muzzin, P., Fulpius, T., Buchs, N. & Vischer, T. L. (2001). Indirect evidence of intra-articular immunoglobulin G synthesis in patients with *Chlamydia trachomatis* reactive arthritis. *Rheumatology (Oxford)* **40**, 801–805.
- Blaine, T. A., Kim, Y. S., Voloshin, I., Chen, D., Murakami, K., Chang, S. S., Winchester, R., Lee, F. Y., O'Keefe, R. J. & Bigliani, L. U. (2005). The molecular pathophysiology of subacromial bursitis in rotator cuff disease. *J Shoulder Elbow Surg* **14** (Suppl. S), 84S–89S.
- Cruz, M. H., Hansen, K., Faarvang, K. L. & Link, H. (1990). Intrasynovial production of oligoclonal specific antibodies in Lyme arthritis. *N Engl J Med* **322**, 1889–1890.
- Hu, L. T., Eskildsen, M. A., Masgala, C., Steere, A. C., Arner, E. C., Pratta, M. A., Grodzinsky, A. J., Loening, A. & Perides, G. (2001). Host metalloproteinases in Lyme arthritis. *Arthritis Rheum* **44**, 1401–1410.
- Kleiner, D. E. & Stetler-Stevenson, W. G. (1994). Quantitative zymography: detection of picogram quantities of gelatinases. *Anal Biochem* **218**, 325–329.
- Lucero, N. E., Foglia, L., Ayala, S. M., Gall, D. & Nielsen, K. (1999). Competitive enzyme immunoassay for diagnosis of human brucellosis. *J Clin Microbiol* **37**, 3245–3248.
- Mousa, A. R., Muhtaseb, S. A., Almudallal, D. S., Khodeir, S. M. & Marafie, A. A. (1987). Osteoarticular complications of brucellosis: a study of 169 cases. *Rev Infect Dis* **9**, 531–543.
- Murphy, G. & Nagase, H. (2008). Reappraising metalloproteinases in rheumatoid arthritis and osteoarthritis: destruction or repair? *Nat Clin Pract Rheumatol* **4**, 128–135.
- Pourbagher, A., Pourbagher, M. A., Savas, L., Turunc, T., Demiroglu, Y. Z., Erol, I. & Yalcintas, D. (2006). Epidemiologic, clinical, and imaging findings in brucellosis patients with osteoarticular involvement. *AJR Am J Roentgenol* **187**, 873–880.
- Shin, J. J., Glickstein, L. J. & Steere, A. C. (2007). High levels of inflammatory chemokines and cytokines in joint fluid and synovial tissue throughout the course of antibiotic-refractory Lyme arthritis. *Arthritis Rheum* **56**, 1325–1335.
- Small, L. N. & Ross, J. J. (2005). Suppurative tenosynovitis and septic bursitis. *Infect Dis Clin North Am* **19**, 991–1005.
- Snoek-van Beurden, P. A. & Von den Hoff, J. W. (2005). Zymographic techniques for the analysis of matrix metalloproteinases and their inhibitors. *Biotechniques* **38**, 73–83.
- Taşova, Y., Saltoğlu, N., Sahin, G. & Aksu, H. S. (1999). Osteoarticular involvement of brucellosis in Turkey. *Clin Rheumatol* **18**, 214–219.
- Traboulsi, R., Uthman, I. & Kanj, S. S. (2007). Prepatellar *Brucella melitensis* bursitis: case report and literature review. *Clin Rheumatol* **26**, 1941–1942.
- Voloshin, I., Gelinas, J., Maloney, M. D., O'Keefe, R. J., Bigliani, L. U. & Blaine, T. A. (2005). Proinflammatory cytokines and metalloproteases are expressed in the subacromial bursa in patients with rotator cuff disease. *Arthroscopy* **21**, 1076.
- Zimmermann, B., III, Mikolich, D. J. & Ho, G., Jr (1995). Septic bursitis. *Semin Arthritis Rheum* **24**, 391–410.
- Zwerdling, A., Delpino, M. V., Barrionuevo, P., Cassataro, J., Pasquevich, K. A., García Samartino, C., Fossati, C. A. & Giambartolomei, G. H. (2008). *Brucella* lipoproteins mimic dendritic cell maturation induced by *Brucella abortus*. *Microbes Infect* **10**, 1346–1354.